The Insular Lobe: Physiopathological and Surgical Considerations

Hugues Duffau, M.D., Laurent Capelle, M.D., Manuel Lopes, M.D., Thierry Faillot, M.D., Jean-Pierre Sichez, M.D., Denis Fohanno, M.D.

Department of Neurosurgery, Hôpital de la Salpêtrière, Paris, France

OBJECTIVE: Surgery of the insula represents a technical challenge, because of the proximity of the internal capsule to the lenticulostriate arteries and the lack of certainty concerning its functionality. Using intraoperative direct cerebral stimulation, combined with neuronavigation, the authors operated on 12 insular gliomas. On the basis of this experience, the physiopathological and surgical implications are discussed.

METHODS: A low-grade insular glioma, revealed by seizures, was diagnosed in 12 right-handed patients with a normal neurological status. Preoperative magnetic resonance imaging showed that, according to Yaşargil's classification system, three patients harbored Type 3 lesions and nine patients had Type 5 lesions (10 tumors on the right side and 2 on the left dominant side). All patients underwent surgery using direct cerebral stimulation, under general anesthesia in nine patients (motor mapping) and under local anesthesia in three patients (sensorimotor and language mapping). Ultrasonography and/or neuronavigation was used in all cases. Preoperative angio-computed tomographic scanning showed the lenticulostriate arteries in two patients.

RESULTS: The internal capsule was systematically detected, and the language areas were identified within the left insula in the awake patients. The lenticulostriate arteries were seen in two patients. Seven patients presented an immediate postoperative deficit; six of them recovered completely within 3 months. Four resections were total, six were subtotal, and two were partial (left insula).

CONCLUSION: The use of intraoperative direct cerebral stimulation and neuronavigation allows surgery of the insula with minimization of the risk of sequelae, but its use is still limited with regard to the dominant hemisphere, owing to the essential role of this structure in language. (Neurosurgery 47:801–811, 2000)

Key words: Direct electrical stimulations, Image-guided surgery, Insula, Language, Motor, Surgery

The insular lobe is a complex structure constituting an anatomic, cytoarchitectonic, and functional interface between the allocortex and the neocortex. This area is part of a larger system that includes the orbitofrontal, temporopolar, and insular regions, constituting the paralimbic system or mesocortex.

For a long time, the difficulty in studying this entity accounted for the poor understanding of its precise functionality, and because of the technical complexity in approaching and dissecting this region, very few neurosurgeons attempted surgery of the insula (7, 36, 42, 43, 59, 65, 73, 76, 77). New developments in functional neuroimaging methods have begun to permit better analysis of the physiopathology of this structure in healthy volunteers as well as in patients with brain diseases (2, 11–14, 16, 17, 33, 35, 44, 46–48, 50, 60, 63, 67, 88); in addition, new surgical techniques have recently generated a more interventionist attitude regarding insular lesions (27, 79, 87, 89).

In the present study, we report our preliminary experience with surgery of insular gliomas in 12 patients, with an analysis of the clinical, functional, and electrophysiological results; on the basis of these findings, we discuss the physiopathological role of this entity and draw some conclusions about the present feasibility and limitations of insular surgery.

PATIENTS AND METHODS

Patient population

We prospectively studied a consecutive series of 12 patients who underwent operations in our institution, from June 1998

to August 1999, for a low-grade glioma involving the insular region. The hemispheric dominance was defined using neuropsychological examination and/or functional magnetic resonance imaging (MRI0 (8, 21).

The classification proposed by Yaşargil et al. (87) was used to categorize the location of the tumors seen on the preoperative MRI scan. Type 3 tumors are restricted to the insula or to parts of it (Type 3A) or may include the corresponding opercula (Type 3B); in addition to the insula and the opercula, Type 5 tumors involve one or both other paralimbic-frontoorbital, temporopolar areas (Type 5A) and/or parts of the limbic system (Type 5B).

An angio-computed tomographic (CT) scan was obtained in two patients (the last two patients of our series) to analyze the relationships between the vessels (in particular, the lenticulostriate arteries [LSAs]) and the tumor. No angiography was performed.

Surgical procedure

All surgical procedures were performed by two operators (HD and/or LC). All patients underwent surgery using direct cortical-subcortical electrical stimulation (direct cerebral stimulation, DCS), under general anesthesia to allow motor mapping or under local anesthesia in awake patients to allow sensorimotor and language mapping. The method of brain stimulation used (biphasic current, pulse frequency of 60 Hz, single pulse phase duration of 1 ms, amplitude from 0.5 to 16 mA, depending on the conditions of anesthesia) (Ojemann cortical stimulator, Radionics, Inc., Burlington, MA) was previously described by the authors (24, 25).

In all cases, patients were installed in a lateral position, and a wide frontotemporopterional boneflap was created. This exposure allowed the identification of the whole sylvian fissure, and it allowed the surgeon to perform cortical motor mapping to detect the primary motor areas of the face and hand and to define the current threshold that would be used during resection to map the subcortical pyramidal pathways. In awake patients, somatosensory and language cortical mapping (counting and naming tasks) was also performed before resection. A delimitation of the tumor boundaries was performed systematically, using ultrasonography and/or an image-guided system (Surgiscope; Elekta AB, Stockholm, Sweden).

To avoid retraction of opercular structures, we preferred in all procedures to begin by frontal and/or temporal tumor resection, which gives a better exposure of the insular surface (with respect to the language sites in the dominant hemisphere). Then, if the lesion involved the posterosuperior part of the right insula, the primary motor area of the face was removed (with preservation using DCS of the primary motor cortical sites and subcortical fibers of the superior limb), since it is known that there is recovery after resection of the nondominant motor face area (49), with the goal of better exposing the infiltrated insula under the central operculum. In patients whose tumor involved the insula only (Type 3A) (nondominant side), we first resected a part of the superior temporal gyrus, without any opercular or venous traction during the insular surgery.

After insular exposure, the middle cerebral artery and its branches, particularly the opercular arteries, were identified. On the dominant side, language mapping was repeated on the insular cortex, with identification and preservation of the eloquent sites. During insular subpial resection, the image-guided system was regularly used to evaluate the distance to the internal capsule (IC). When the IC was approached, resection was frequently alternated with repetitive DCS until a motor response was obtained. The temporal horn was often opened at the level of the inferior circular sulcus; then identification in the posterior area proceeded, starting with the motor descending pathways of the inferior limb, which are anatomically closer to the insular surface than the fibers of the anterior limb, and of the face, at the middle and anterior part of the IC, respectively. These fibers were then identified while resection and repetitive DCS continued in a caudorostral fashion, with eventual removal of the infiltrated lentiform nucleus. At the superior part of the insula, the resection beyond the level of the superior circular sulcus led immediately into the centrum semiovale at the point where the fibers of the face and the superior limb fan out. In patients with initial resection of the primary face area, since the fibers were first detected at the level of the centrum semiovale, the resection was conducted from top to bottom. In all cases, the rolandic artery had to be cautiously identified and dissected at this level. In awake patients, during this stage of resection, while the operator was in contact with the motor pathways, DCS was performed frequently; to monitor the functions of the exposed areas, DCS was alternated with simple commands to the patient (raise the arm, open and close the hand, move the foot). Moreover, for patients with a tumor in the dominant hemisphere, a continuous conversation and/or naming task was maintained during the entire lesion removal; when any mild language hesitation appeared during stimulation and/or resection, surgery was immediately stopped.

Anteriorly, after removal of the limen insulae at the bifurcation of the sylvian artery, one of the most dangerous areas remains; it leads to the anterior perforating substance, which carries a major risk of damage to the LSAs and thus represents an anatomic boundary of the resection. Ultrasonography and image-guided surgery were repeatedly used throughout the procedure to determine the amount and exact location of the remaining tumor; the resection could then continue if the residual lesion did not invade functional brain tissue, as identified using electrophysiological methods.

At the end of the resection, and before closure, we systematically performed cortical stimulation on the surface of the primary hand and/or face motor areas to check the anatomofunctional integrity of the pyramidal pathways; indeed, if the DCS induced the same motor responses at the same current intensity at the same sites as before the resection, it became certain that the patient would recover full motor function, even if there were deficits in the immediate postoperative period (25).

Postoperative course

The quality of the resection was systematically evaluated by early postoperative MRI (in the first 24 h). With the aim of achieving a total removal, four patients were reoperated after a short delay (from 36 h to 1 mo) to remove tumoral residue from the first surgery. Delayed serial MRI studies were then performed 3 months after surgery and at 6-month intervals. Pre- and postoperative T1-, T2-, and proton density-weighted images were obtained in all cases and were compared by two neurosurgeons. The patients were assigned to one of three classes, according to the classification proposed by Berger et al. (5) for estimation of the extent of low-grade glioma removal: total resection when absolutely no postoperative signal abnormality was detected, subtotal resection when the volume of residual tumor was less than 10 cc, and partial removal when this volume was 10 cc or more.

RESULTS

Patient data and results are summarized in *Table 1*.

Patient characteristics

The series consisted of six men and six women, ranging in age from 24 to 56 years (mean, 38 yr). All patients were right-handed. The presenting symptoms were seizures in all cases, five generalized and seven partial: transitory dysphasia (two patients), sensorimotor symptoms (two patients), visceral sensation (two patients), and auditory phenomena (one patient). The clinical examination was normal in all 12 patients.

Preoperative MRI revealed that, according to the classification of Yaşargil et al. (87), three patients in our series harbored Type 3 lesions (one patient with Type 3A and two with Type 3B), and nine patients had Type 5 lesions (five patients with Type 5A and four with Type 5B; five of these patients had infiltration of the three parts [insular, fronto-orbital, and temporopolar] of the paralimbic system). With regard to the depth of tumor extension, the lentiform nucleus was invaded in nine cases. Ten lesions involved the right, nondominant hemisphere, and two involved the left, dominant side. The median tumor volume was 95 cc (range, 5–185 cc). The LSAs were visualized on the preoperative angio-CT scan in two patients.

Surgical data

Surgical approach

Before insular resection, an isolated temporal lobectomy was performed in three patients, an isolated frontal removal in three patients, and an associated wide frontotemporal resection in five patients. The nondominant, noninfiltrated middle part of the superior temporal gyrus was resected in the remaining patient (a patient with tumor Type 3A). Furthermore, the nondominant, noninfiltrated primary motor face area was removed in two patients to allow a better insular exposure.

Electrophysiological findings

DCS was performed under general anesthesia in nine patients with motor mapping and under local anesthesia in three awake patients (in one patient at the beginning of our experience to refine motor mapping, in the two others to perform language mapping also, because of the location of the tumor on the left side). The primary motor area was identified in all cases before resection, without "negative mapping." There was no motor response directly recorded on the insular cortex. During insular removal, it was possible to detect the IC in all 12 patients, with reconstitution of its somatotopy, which was modified in two cases compared with the normal anatomofunctional distribution of the fibers (i.e., with the descending pathways of the superior limb behind those of the inferior limb). Postresection cortical stimulation was positive in all patients except one (a patient who was awake during the operation to improve the detection of the motor structures; in this case, tumor removal was stopped because of the occurrence of hemiplegia during surgery).

In the other two awake patients (who had lesions in the dominant hemisphere), the frontotemporal language mapping allowed the identification of essential eloquent areas, which were preserved during the left temporal lobectomy. Additional language sites were then detected on the surface of the left insular cortex in its anterior part, by inducing complete speech arrest by stimulation in the two patients. Resection of the noneloquent parts of the insula was performed more posteriorly, but new episodes of speech arrest rapidly were induced within the depths of the insular lobe, requiring us to stop the surgery, although this region was invaded by tumor, as shown by ultrasonography and neuronavigation.

Vascular findings

The trunk and branches of the middle cerebral artery were dissected and preserved in all patients. The departure of the LSAs was seen systematically, but their course was followed only in two patients. The median duration of the surgical procedure was 8 hours.

Clinical results

There was no operative or postoperative mortality. Seven patients (58%) experienced an immediate postoperative deficit (six motor and one linguistic), in one case remaining in a comatose state for 72 hours. There was one case of temporal venous thrombosis and one case of meningitis. The five patients with infiltration of the three parts of the paralimbic system also presented postoperative slowness of ideation.

Nevertheless, a total recovery (of motor, linguistic, and neuropsychological capacities) was observed in all patients except one, with a delay of 5 days to 3 months. The overall definitive neurological morbidity was thus reduced to 8%, i.e., one patient had left hemiparesis attributable to LSA injury, as confirmed on the postoperative MRI scan (the patient with disappearance of motor response during cortical stimulation at the end of resection).

Histological results

The histopathological examination diagnosed 12 low-grade gliomas (World Health Organization Grade II). Four of them presented with high labeling indices of MIB-1 antibody to Ki-67

TABLE 1. Clinical, Radiological, and Surgical Characteristics of the 12 Patients with Glioma Involving the Insular Region[a]

Patient No.	Sex/Age (yr)	Presenting Symptoms	Clinical Examination	MRI Classification of Yaşargil	Surgical Data	Immediate Postoperative Neurological Results	Neurological Outcome 3 Months after Surgery	Quality of Resection
1	F/35	Auditory partial seizures	Normal	Right temporoinsular glioma, Type 5A	GA, temporal lobectomy, then insular resection, identification of IC, LSAs not followed	Normal	Normal	Total
2	F/26	Generalized seizures	Normal	Right operculoinsular glioma, Type 3B	GA, frontoopercular resection, then insular resection, identification of IC, LSAs not followed	Normal	Reoperation 1 mo later, normal status	Subtotal
3	F/44	Phasic partial seizures	Normal	Left temporoinsular glioma, Type 5A	LA, temporal lobectomy, partial insular resection due to infiltration of language areas, identification of IC, LSAs not followed	Transitory dysphasia	Normal	Partial
4	F/56	Visceral partial seizures	Normal	Right frontotemporoinsular glioma, Type 5A	GA, frontotemporal lobectomy, then insular resection, identification of IC, LSAs not followed	Transitory motor and neuro-psychological deficit	Normal	Subtotal
5	M/31	Sensorimotor partial seizures	Normal	Right temporoinsular glioma, Type 5A	GA, temporal lobectomy, then insular resection, identification of IC, LSAs not followed	Normal	Normal	Subtotal
6	F/38	Generalized seizures	Normal	Right frontotemporoinsular glioma, Type 5B	GA, frontotemporal lobectomy, then insular resection, identification of IC, LSAs not followed	Transitory motor and neuro-psychological deficit, temporal venous thrombosis	Normal	Subtotal
7	F/37	Phasic partial seizures	Normal	Left frontoinsular glioma, Type 5A	LA, partial frontal resection, partial insular resection due to infiltration of language areas, identification of IC, LSAs not followed	Normal	Normal	Partial
8	M/32	Visceral partial seizures	Normal	Right frontotemporoinsular glioma, Type 5B	LA, frontotemporal lobectomy, then insular resection, identification of IC, LSAs not followed	Transitory motor and neuro-psychological deficit	Reoperation 3 wk later, left hemiparesis	Subtotal
9	M/38	Sensorimotor partial seizures	Normal	Right insular glioma, Type 3A	GA, partial resection of STG, then insular resection, identification of IC, LSAs not followed	Normal	Reoperation 36 h later, normal	Total
10	M/50	Generalized seizures	Normal	Right operculoinsular glioma, Type 3B	GA, fronto-opercular resection, then insular resection, identification of IC, LSAs not followed	Transitory motor deficit	Normal	Subtotal
11	M/24	Generalized seizures	Normal	Right frontotemporoinsular glioma, Type 5B	GA, frontotemporal lobectomy, then insular resection, identification of IC, LSAs followed	Transitory motor and neuro-psychological deficit	Reoperation 15 d later, normal	Total
12	M/37	Generalized seizures	Normal	Right frontotemporoinsular glioma, Type 5B	GA, frontotemporal lobectomy, then insular resection, identification of IC, LSAs followed	Transitory motor and neuro-psychological deficit	Normal	Total

[a] MRI, magnetic resonance imaging; GA, general anesthesia; LA, local anesthesia; IC, internal capsule; LSAs, lenticulostriate arteries; STG, superior temporal gyrus.

antigen, which seems to represent the wrong prognostic significance marker (68), motivating complementary irradiation.

Quality of resection

Four resections were considered total (i.e., without any signal abnormality), as evaluated by postoperative MRI; two patients had transient motor deficits and two had slowness of ideation. Six resections were assessed as subtotal (<10 cc of tumor remaining); four of these patients had transient motor deficits, and three had slowness of ideation. Two resections were considered partial; one patient had transient dysphasia. The mean follow-up period for the series is 15 months (range, 8–22 mo).

ILLUSTRATIVE CASE

A 37-year-old right-handed man (*Table 1*, Patient 12) presented generalized seizures without neurological deficit at clinical examination. The axial MRI view showed a right frontotemporoinsular glioma, also involving the limbic system (Type 5B) (*Fig. 1*).

Surgery was performed under general anesthesia, with delimitation of the tumor boundaries using neuronavigation and ultrasonography (*Fig. 2*; sterile tag letters are placed on the cortical surface), and cortical mapping of the face and hand primary motor area using DCS (marked by tag numbers) before resection (*Fig. 3*). The temporal and frontal parts of the tumor were removed first, allowing good exposure of the insular cortex. The insula was then resected, with detection and preservation of the IC in its depth (marked by tag numbers) and arrest of the surgery at the level of the anterior perforating substance (*Fig. 4*). DCS performed at the end of tumor removal still induced the same motor response of the face and hand as before resection.

The patient presented an immediate postoperative transitory left hemiparesis and slowness of ideation, both of which were completely resolved within 2 months. Postoperative MRI showed total removal of the lesion (*Fig. 5*), confirmed by absence of neoplastic cells on the histological examination of the walls of the surgical cavity.

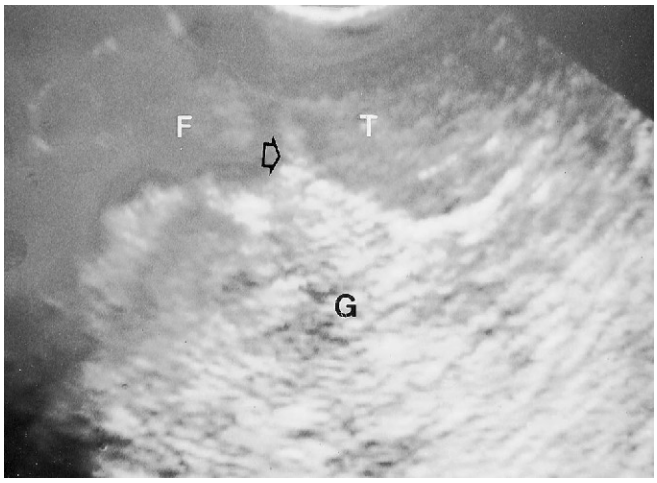

FIGURE 2. Intraoperative pre-resection ultrasonographic image (coronal view, 5 cm depth), showing the sylvian fissure (*arrow*), the frontal cortex (*F*), the temporal cortex (*T*), and the insula infiltrated by the glioma (*G*).

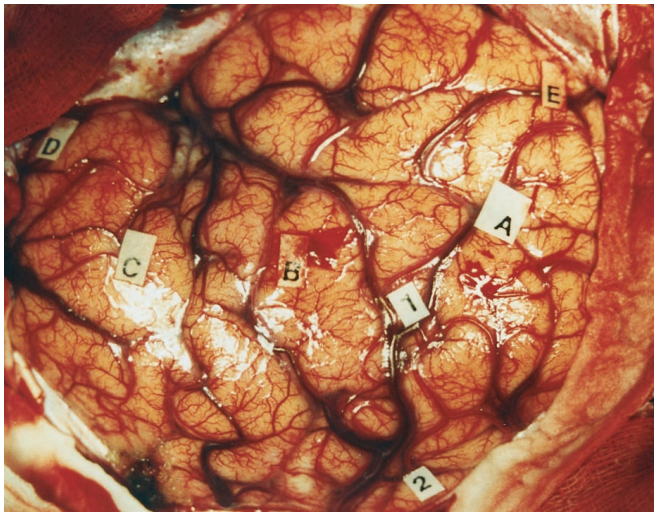

FIGURE 3. Intraoperative pre-resection photograph. The wide frontotemporal exposure allows the detection of the tumor boundaries using an image-guided surgery system coupled with ultrasonography (limits marked by *sterile tag letters*), and the identification of the primary motor face (*Number 1*) and hand (*Number 2*) areas using DCS under general anesthesia.

DISCUSSION

Physiopathological considerations

The progress made in the understanding of the insula using anatomic studies (78, 80), cytoarchitectonic considerations (1), animal experiments (38, 70, 75), intraoperative electrical stimulation in humans (54, 57, 59), and, more recently, noninvasive functional neuroimaging methods (2, 13, 14, 16, 17, 33, 44, 46, 47, 60, 67) has allowed us to envisage this entity as an active relay connecting the limbic system to the neocortex (52), with participation in many functions: a sensory role (10, 36, 53, 59, 65, 69, 70, 85, 89), a motor role (9, 17, 20, 31, 32, 59, 82, 84), a limbic integration role (12, 34, 35, 63, 75), an auditory-vestibular role (11, 37, 38, 61, 64), and a cognitive role (18, 48, 50, 58), particularly in language (22, 40, 54, 62, 67, 72, 88). Our present experience further argues for the participation of the insula in such functions.

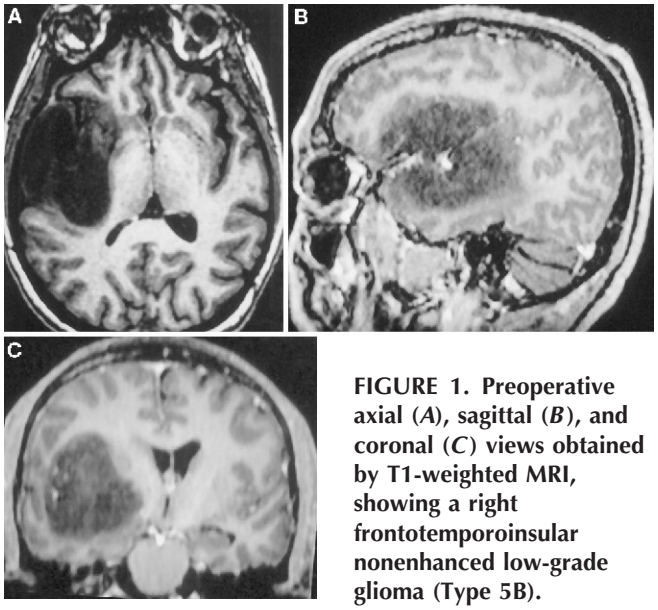

FIGURE 1. Preoperative axial (*A*), sagittal (*B*), and coronal (*C*) views obtained by T1-weighted MRI, showing a right frontotemporoinsular nonenhanced low-grade glioma (Type 5B).

The presenting symptoms

Our seven patients with partial seizures experienced transitory dysphasia, auditory phenomena, sensorimotor symptoms, and visceral sensation, which represent the insular characteristics usually attributed to seizures induced by tumors of the paralimbic system (15, 32, 89).

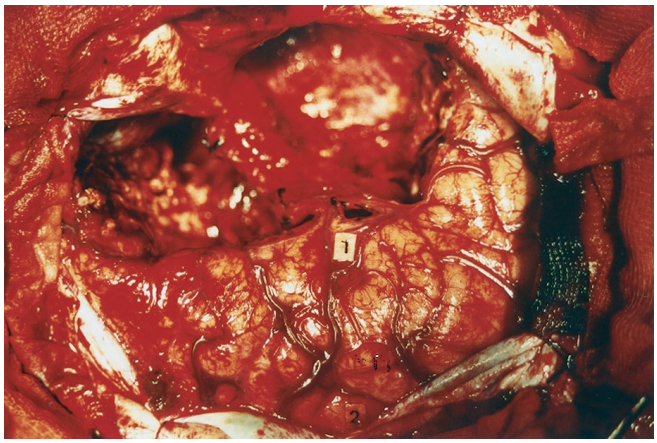

FIGURE 4. Intraoperative postresection photograph, showing frontotemporoinsular removal, with preservation of the middle cerebral artery and its branches, the cortical motor sites (*Numbers 1* and *2*), and the IC, since the stimulations deep in the cavity induce motor responses of the face and superior and inferior limbs.

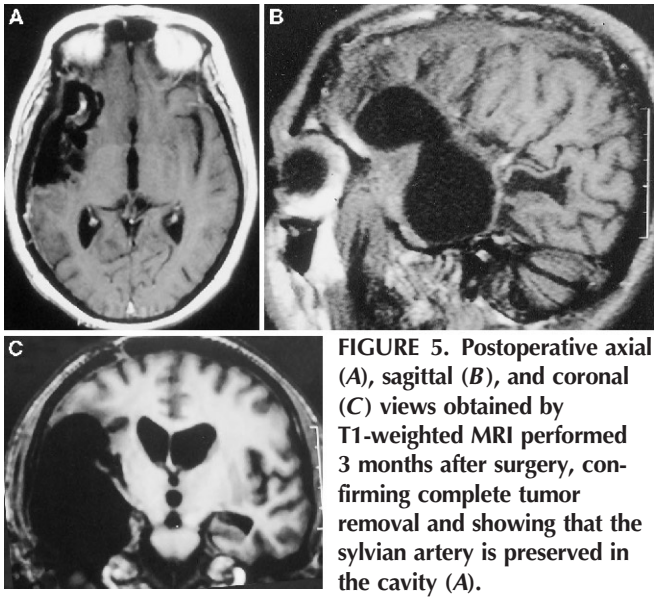

FIGURE 5. Postoperative axial (*A*), sagittal (*B*), and coronal (*C*) views obtained by T1-weighted MRI performed 3 months after surgery, confirming complete tumor removal and showing that the sylvian artery is preserved in the cavity (*A*).

The intraoperative electrophysiological findings

If somatic, visceral sensorimotor, and vestibular-auditory response were not induced during the perioperative functional insular mapping, notably on awake patients, a systematic speech arrest was generated by electrical stimulation of the dominant insula. This result favors the recent hypothesis that envisages that the insular cortex is an essential area for the motor planning of speech (22). However, the insula has traditionally not been specified as important in studies of speech and language localization. One exception is a report in which electrocortical stimulation of the insula during epilepsy surgery produced word-findings errors (54). More recently, Ebeling and Kothbauer (27) also described intraoperative severe dysphasia (and weakness of the superior limb) during an operation for glioma involving the dominant insula, which prevented resection. Moreover, some authors have mentioned language disorders in insular vascular lesions (22, 40, 50) and an involvement of the insular structure in conduction aphasia (19). Finally, a number of recent neurofunctional imaging studies have shown activation of the dominant insula in tasks involving speech (58, 62, 67, 88).

These findings of a high probability that the left insular lobe is an essential area for coordinating speech articulation imply a risk that would limit insular surgery in the dominant hemisphere. This risk is increased in glioma surgery, owing to the infiltrative nature of these lesions, with possible preservation of function in spite of brain invasion (55, 74). Indeed, in two patients in our series, preoperative MRI and intraoperative ultrasonography demonstrated that the whole left insula was clearly involved by the tumor, but, nevertheless, speech arrest was elicited by each stimulation. Since it is now well known that electrical stimulation detects eloquent areas that are essential (i.e., noncompensable) for language (41, 56), this finding indicates that the insular lobe was really still functional in our two patients.

The postoperative clinical course

Six patients experienced a motor deficit 5 days to 3 months after surgery (a delay too great to explain this paresis as due to postoperative edema), with total recovery in all cases except for one patient with vascular injury (as demonstrated on postoperative MRI, which showed ischemia in the posterior limb of the IC). This transient paresis was not correlated to the extent of removal: indeed, motor deficits occurred in two (50%) of four patients with total resections and four (66%) of six patients with subtotal resections. Since primary motor cortical-subcortical structures were identified and preserved using intraoperative DCS in all patients, these results suggest that the insula probably has a role as a secondary or additional motor area, as previously reported (1, 9, 31), i.e., it is participates but is not essential to voluntary movement, with the possibility of being compensated by functional reorganization mechanisms. This hypothesis is strengthened by the anatomic connections between the insula and the premotor cortex; this circuitry already suggests that the insula may have a role in poststroke recovery of motor function (16, 17, 82).

Moreover, five patients exhibited transitory postoperative neuropsychological worsening; these results further argue in favor of the probable participation of the insula (including the nondominant lobe) in cognitive functioning. However, it seems that, contrary to language functioning, the dysfunction of a single insular lobe does not generate impairment of these cognitive processes. Indeed, the only patients with these symptoms in our series were those who underwent resection of the whole paralimbic system (i.e., frontotemporoinsular resection). Interestingly, tumoral involvement of the limbic system does not seem to directly influence this postoperative neuropsychological deficit, as there were two patients with Type 5A tumors and three patients with Type 5B tumors. Precise preoperative analysis of fronto-orbital and temporopolar infiltration should represent a good predictive pa-

rameter for evaluation of the risk of postoperative transient cognitive worsening.

In all cases, motor and neuropsychological recovery indicates that insular functional participation was probably compensated by brain plasticity mechanisms, as has been suggested previously with regard to the central areas (26, 29, 71). A better understanding of the regions that might assume this functional reorganization could be acquired by studying the correlations between pre- and postoperative neurofunctional imaging, a study in progress in our institution.

Surgical considerations

Only a few surgical series centered on the insular lobe have been published. Two early reports describing insular resection for seizure control deplored a high rate of complications (59, 73). During the following decades, some authors published reports of successful transinsular approaches and/or insular lesion removals, but these series included only a limited number of patients harboring small, well-delimited tumors (7, 36, 42, 43, 65, 76, 77). More recently, several teams have attempted to perform resection of insular infiltrative gliomas using new surgical methods (27, 79, 87, 89), because studies with long-term follow-up during the past decade have shown that surgical resection of low-grade gliomas in brain locations other than the insular lobe improves both quality of life and median survival (5, 23, 28, 51, 83). Although removal of insular gliomas seems achievable in some cases, two major problems remain, in addition to the functionality of the insular lobe, which has already been discussed: the detection of the IC and the preservation of the LSAs.

The detection of the IC

According to Yaşargil (87), the IC is protected by the gray nuclei and more laterally by the claustrum, which represents the limit of resection, since it can be identified well under the operative microscope as an area that is spared by the tumor (perhaps because gliomas have an affinity for phylogenetically primitive zones [30, 86]). However, we found the claustrum and the lentiform nucleus to be invaded by the tumor in nine patients in our series (75%), and it was not possible to use anatomic criteria alone to preserve the IC in a attempt to perform the most complete resection. Because of the same observation of diffuse medial tumor infiltration in several patients, Zentner et al. (89) proposed two intraoperative aids: the use of stereotactic marking and the monitoring of somatosensory and/or motor evoked potentials, although both of these aids represent only indirect methods of detection of the IC.

Vanaclocha et al. (79) reported awakening patients with the aim of asking them to perform motor tasks during the resection; the limitations of this method are the risk of noting motor weakness when the IC is already damaged and the risk of incurring great fatigue during a protracted operation when the awakening seems inessential (i.e., when the lesion is in the nondominant hemisphere). Indeed, in our study, we tried to perform the surgical procedure under local anesthesia in one case of glioma involving the right insular region. The patient became hemiplegic during the resection, despite the fact that the surgical cavity was separated from the IC by a distance of more than 1 cm (as shown particularly by neuronavigation), and the operation was stopped for functional reasons in spite of evident tumor residue. The patient totally recovered in 1 week, confirming the preservation of the pyramidal pathways, but a reoperation was necessary (under general anesthesia). Furthermore, we also used a stereotactic image-guided system to detect the IC; even if it proved to be a substantial aid, particularly at the beginning of the operation, we found that, after a wide resection (at a time when identification of the IC is mandatory), there was a median shift of at least 4 mm, including the depth, as previously reported in the literature (3, 39, 45).

For all of these reasons, we propose the systematic use of intraoperative subcortical electrical stimulation, which represents, in our experience, an easy, safe, accurate, and reliable method of direct detection of the IC, as previously mentioned (6). Indeed, we identified and preserved the descending pyramidal pathways in all cases (e.g., the IC and the corona radiata in the case of associated frontal resection). Moreover, we resected the primary motor face area of the nondominant hemisphere in two cases, with postoperative recovery (49): in these two patients, the cortical-subcortical stimulation allowed us to differentiate the motor face structures from the motor hand regions, which it is imperative to respect. Using these brain mapping methods, it becomes possible to perform glioma surgery using functional and not anatomic boundaries in the insular location, as has been reported for other cerebral sites (4, 24, 25), allowing the risk of definitive postoperative sequelae to be minimized and the quality of resection to be optimized. In 83% of our patients, a total (33%) or subtotal (50%) resection was confirmed by postoperative (early and late) T1- and T2-weighted MRI (in comparison, only 17% of 30 patients exhibited an absence of any sign of tumor on MRI in the recent series of Zentner et al. [89]), and only 8% of our patients had sequelae. To improve these results, we agree with Ebeling and Kothbauer (27) and recommend the more systematic use of early reoperation if residual tumor is proven on MRI in a noneloquent area (i.e., an area without any functional—motor or linguistic—response to stimulation during the first surgery), as was done in four patients in our series.

The preservation of the LSAs

Detection of the LSAs remains one of the challenges of insular surgery. Indeed, even with the dissection of the trunk of the middle cerebral artery and identification of the departure of the LSAs (taking into account interindividual anatomic variability [66, 81]), it becomes very difficult to follow these arteries when they penetrate the parenchyma, because of their number (2–13) and small diameter (around 1 mm). These considerations explain why Yaşargil et al. (87) and Ebeling and Kothbauer (27) suggested leaving a layer of tumor tissue along the uncinate bundle so as to avoid injury to these vessels, and why Vanaclocha et al. (79) ascribed one case of severe neurological worsening to damage to the LSAs. In our

series, one patient had definite hemiparesis, probably secondary to vascular injury, although there was no direct visualization of LSA damage by the surgeon during resection.

To reduce this morbidity, Yaşargil et al. (87) advised performing systematic preoperative angiography, which would permit the surgeon to analyze the course of the two main trunks of LSAs (internal and external). To avoid performing an invasive angiogram, we tried to detect these LSAs using a noninvasive angio-CT scan in the last two patients in our series: the course of the perforating arteries was visible in the two patients, and it was possible to analyze the anatomic distortion induced by the mass effect due to the tumor. Now in progress in our institution is a project to integrate this three-dimensional angio-CT scan into the stereotactic image-guided system, with the goal of beginning the surgery with opening of the sylvian fissure, dissection of the middle cerebral artery, and detection of the LSAs before performing a wide resection to avoid any shift. As neuronavigation progresses, particularly in combination with ultrasonography, which will allow real-time patient-image coregistration, will likely improve the accuracy of computer-assisted microneurosurgery, which may become very useful for the intraoperative detection of the LSAs.

CONCLUSION

A better knowledge of the physiopathology of the insula, in addition to the use of intraoperative functional brain mapping and stereotactic neuronavigation methods for detection of the IC and LSAs, now allows surgery of the insula to be performed with minimization of the risk of neurological sequelae, although there is still a limitation on the dominant hemisphere because of the essential role of this structure in language. The indications for surgical resection of nondominant insular lesions, notably gliomas, should be considered more systematically. Furthermore, a study correlating neurofunctional imaging before and after surgery to understand the mechanisms of functional reorganization, should allow us to predict each patient's individual ability to recover.

Received, November 9, 1999.
Accepted, May 22, 2000.
Reprint requests: Hugues Duffau, M.D., Service de Neurochirurgie 1, Hôpital de la Salpêtrière, 47 Boulevard de l'Hôpital, 75651 Paris 13, France. Email: hugues.duffau@psl.ap-hop-paris.fr

REFERENCES

1. Augustine JR: Circuitry and functional aspects of the insular lobe in primates including humans. **Brain Res Brain Res Rev** 22:229–244, 1996.
2. Aziz Q, Anderson JC, Valind S, Sundin A, Hamdy S, Jones AK, Foster LR, Largstrom B, Thompson DG: Identification of human brain loci processing oesophageal sensation using positron emission tomography. **Gastroenterology** 113:50–59, 1997.
3. Barnett GH, Kormos DW, Steiner PC, Weisenberger J: Use of a frameless, armless stereotactic wand for brain tumor localization with two-dimensional and three-dimensional neuroimaging. **Neurosurgery** 33:674–678, 1993.
4. Berger MS, Ojemann GA: Intraoperative brain mapping techniques in neuro-oncology. **Stereotact Funct Neurosurg** 58:153–161, 1992.
5. Berger MS, Deliganis AV, Dobbins JD, Keles GE: The effect of extent of resection on recurrence in patients with low grade cerebral hemisphere gliomas. **Cancer** 74:1784–1791, 1994.
6. Berger MS, Ojemann GA, Lettich E: Neurophysiological monitoring during astrocytoma surgery. **Neurosurg Clin N Am** 1:65–80, 1990.
7. Bertalanffy H, Gilsbach JM, Eggert HR, Seeger W: Microsurgery of deep-seated cavernous angiomas: Report of 26 cases. **Acta Neurochir (Wien)** 108:91–99, 1991.
8. Binder JR, Swanson SJ, Hammeke TA, Morris GL, Mueller WM, Fischer M, Benbadis S, Frost JA, Rao SM, Haughton VM: Determination of language dominance using functional MRI: A comparison with the Wada test. **Neurology** 46:978–984, 1996.
9. Blinkenberg M, Bonde C, Holm S, Svarer C, Andersen J, Paulson OB, Law I: Rate dependence of regional cerebral activation during performance of a repetitive motor task: A PET study. **J Cereb Blood Flow Metab** 16:794–803, 1996.
10. Bonda E, Petrides M, Evans A: Neural systems for tactual memories. **J Neurophysiol** 75:1730–1737, 1996.
11. Bottini G, Sterzi R, Paulesu E, Vallar G, Cappa SF, Reminio F, Passingham RE, Frith CD, Frackowiak RS: Identification of the central vestibular projection in man: A positron emission tomography activation study. **Exp Brain Res** 99:164–169, 1994.
12. Buchel C, Morris J, Dolan RJ, Friston KJ: Brain systems mediating aversive conditioning: An event related fMRI study. **Neuron** 20: 947–957, 1998.
13. Bucher SF, Dieterich M, Seelos KC, Brandt T: Sensorimotor cerebral activation during optokinetic nystagmus: A functional MRI study. **Neurology** 49:1370–1377, 1997.
14. Burton H, Videen TO, Raichle ME: Tactile-vibration-activated foci in insular and parietal-opercular cortex studied with positron emission tomography: Mapping the second somatosensory area in humans. **Somatosens Mot Res** 10:297–308, 1993.
15. Cascino GD, Karnes WE: Gustatory and second sensory seizures associated with lesions in the insular cortex seen on magnetic resonance imaging. **J Epilepsy** 3:185–187, 1990.
16. Chollet F, DiPiero V, Wise RJS, Brooks DJ, Dolan RJ, Frackowiak RSJ: The functional anatomy of motor recovery after stroke in humans: A study with positron emission tomography. **Ann Neurol** 29:63–71, 1991.
17. Colebatch JG, Deiber MP, Passingham RE, Friston KJ, Frackowiak RSJ: Regional cerebral blood flow during voluntary arm and hand movements in human subjects. **J Neurophysiol** 65:1392–1401, 1991.
18. Corbetta M, Miezin FM, Dobmeyer S, Shulman GL, Petersen SE: Selective and divided attention during visual discrimination of shape, color, and speed: Functional anatomy by positron emission tomography. **J Neurosci** 11:2383–2402, 1991.
19. Damasio H, Damasio AR: The anatomical basis of conduction aphasia. **Brain** 103:337–350, 1980.
20. Daniels SK, Foundas AL: The role of insular cortex in dysphagia. **Dysphagia** 12:146–156, 1997.
21. Desmond JE, Sum JM, Wagner AD, Demb JB, Shear PK, Glover GH, Gabrieli JDE, Morrell MJ: Functional MRI measurement of language lateralization in Wada-tested patients. **Brain** 118:1411–1419, 1995.
22. Dronkers NF: A new brain region for coordinating speech articulation. **Nature** 384:159–161, 1996.

23. Duffau H, Capelle L, Arthuis F, Sichez JP, Bitar A, Faillot T, Van Effenterre R, Fohanno D: Gliomes de bas grade: Plaidoyer pour une chirurgie "large," in *Les Tumeurs du Système Nerveux Central*. Paris, DYK Editions, Revue de la Société Francophone de Cancérologie, 1999, pp 46–52.
24. Duffau H, Capelle L, Sichez JP, Bitar A, Faillot T, Arthuis F, Van Effenterre R, Fohanno D: Preoperative direct cortical and subcortical electric stimulation during cerebral surgery in functional areas [in French]. **Rev Neurol (Paris)** 155:553–568, 1999.
25. Duffau H, Capelle L, Sichez J, Faillot T, Abdennour L, Law Koune JD, Dadoun S, Bitar A, Arthuis F, Van Effenterre R, Fohanno D: Intra-operative direct electrical stimulations of the central nervous system: The Salpêtrière experience with 60 patients. **Acta Neurochir (Wien)** 141:1157–1167, 1999.
26. Duffau H, Sichez JP, Lehéricy S: Intraoperative unmasking of brain redundant motor sites during resection of a precentral angioma: Evidence using direct cortical stimulations. **Ann Neurol** 47:132–135, 2000.
27. Ebeling U, Kothbauer K: Circumscribed low grade astrocytomas in the dominant opercular and insular region: A pilot study. **Acta Neurochir (Wien)** 132:66–74, 1995.
28. Ebeling U, Fischer M, Kothbauer K: Surgery of astrocytomas in the motor and premotor cortex under local anesthesia: Report of 11 cases. **Minim Invasive Neurosurg** 38:51–59, 1995.
29. Fandino J, Kollias SS, Wieser HG, Valavanis A, Yonekawa Y: Intraoperative validation of functional magnetic resonance imaging and cortical reorganization patterns in patients with brain tumors involving the primary motor cortex. **J Neurosurg** 91:238–250, 1999.
30. Filiminoff IN: A rational subdivision of the cerebral cortex. **Arch Neurol Psychiatry** 58:296–311, 1947.
31. Fink GR, Frackowiak RSJ, Pietrzyk U, Passingham RE: Multiple nonprimary motor areas in the human cortex. **J Neurophysiol** 77:2164–2174, 1997.
32. Fiol ME, Leppik IE, Mireles R, Maxwell R: Ictus emeticus and the insular cortex. **Epilepsy Res** 2:127–131, 1988.
33. Fukuda H, Yamada K, Kinomura S, Kawashima R, Ono S, Yoshioka S, Yamaguchi T, Matui H, Itoh M, Seo S: High order gustatory projections in the human brain studied with positron emission tomography, in *The Salt Science Annual Research Report: Section of Physiology and Food Science*. New York, Raven Press, 1991, pp 337–347.
34. George MS, Huggins T, McDermut W, Parekh PL, Rubinow D, Post RM: Abnormal facial emotion recognition in depression: Serial testing in an ultra rapid cycling patient. **Behav Modif** 22:192–204, 1998.
35. Ghaem O, Mellet E, Crivello F, Tzourio N, Mazoyer B, Berthoz A, Denis M: Mental navigation along memorized routes activates the hippocampus precuneus and insula. **Neuroreport** 8:739–744, 1997.
36. Greenspan JD, Winfield JA: Reversible pain and tactile deficits associated with a cerebral tumor compressing the posterior insula and parietal operculum. **Pain** 50:29–39, 1992.
37. Griffiths TD, Rees A, Witton C, Cross PM, Shakir RA, Green GG: Spatial and temporal auditory processing deficits following right hemisphere infarction: A psychophysical study. **Brain** 120:785–794, 1997.
38. Grüsser OJ, Pause M, Schreiter U: Vestibular neurones in the parieto-insular cortex of monkeys (Macaca fascicularis): Visual and neck receptor responses. **J Neurophysiol** 430:559–583, 1990.
39. Gumprecht HK, Widenka DC, Lumenta CB: BrainLab VectorVision Neuronavigation System: Technology and clinical experiences in 131 cases. **Neurosurgery** 44:97–105, 1999.
40. Habib M, Daquin G, Milandre L, Royere ML, Rey M, Lanteri A, Salamon G, Khalil R: Mutism and auditory agnosia due to bilateral insular damage: Role of the insula in the human communication. **Neuropsychologia** 33:327–339, 1995.
41. Haglund MM, Berger MS, Shamseldin M, Lettich E, Ojemann GA: Cortical localization of temporal lobe language sites in patients with gliomas. **Neurosurgery** 34:567–576, 1994.
42. Hatashita S, Sakakibara T, Ishii S: Lipoma of the insula. **J Neurosurg** 58:300–302, 1983.
43. Heffez DS: Stereotactic transsylvian, transinsular approach for deep-seated lesions. **Surg Neurol** 48:113–124, 1997.
44. Hsieh JC, Belfrage M, Stone-Elander S, Hansson P, Ingvar M: Central representation of chronic ongoing neuropathic pain studied by positron emission tomography. **Pain** 63:225–236, 1995.
45. Kato A, Yoshimine T, Hayakawa T, Tomita Y, Ikeda T, Mitomo M, Harada K, Mogami H: A frameless, armless navigational system for computer-assisted neurosurgery. **J Neurosurg** 74:845–849, 1991.
46. Kettenmann B, Hummel C, Stefan H, Kobal G: Multiple olfactory activity in the human neocortex identified by magnetic source imaging. **Chem Senses** 22:493–502, 1997.
47. Kobayakawa T, Endo H, Ayabe-Kanamura S, Kumagai T, Yamagushi Y, Kikuchi Y, Takeda T, Saito S, Ogawa H: The primary gustatory area in human cerebral cortex studied by magnetoencephalography. **Neurosci Lett** 212:155–158, 1996.
48. Kosslyn SM, DiGirolamo GJ, Thompson WL, Alpert NM: Mental rotation of objects versus hands: Neural mechanisms revealed by positron emission tomography. **Psychophysiology** 35:151–161, 1998.
49. LeRoux PD, Berger MS, Haglund MM, Pilcher WH, Ojemann GA: Resection of intrinsic tumors from nondominant face motor cortex using stimulation mapping: Report of two cases. **Surg Neurol** 36:44–48, 1991.
50. Marshall RS, Lazar RM, Mohr JP, Van Heertum RL, Mast H: "Semantic" conduction aphasia from posterior insula cortex infarction. **J Neuroimaging** 6:189–191, 1996.
51. McCormack BM, Miller DC, Budzilovich GN: Treatment and survival of low-grade astrocytoma in adults: 1977–1988. **Neurosurgery** 31:636–642, 1992.
52. Mesulam M, Mufson EJ: The insula of Reil in man and monkey: Architectonics, connectivity, and function, in Peters AA, Jones EG (eds): *Cerebral Cortex*. New York, Plenum Press, 1985, vol 4, pp 179–226.
53. Ogawa H: Gustatory cortex of primates: Anatomy and physiology. **Neurosci Res** 20:1–13, 1994.
54. Ojemann GA, Whitaker HA: Language localization and variability. **Brain Lang** 6:239–260, 1978.
55. Ojemann JG, Miller JW, Silbergeld DL: Preserved function in brain involved by tumor. **Neurosurgery** 39:253–259, 1996.
56. Ojemann GA, Ojemann JG, Lettich E, Berger MS: Cortical language localization in left, dominant hemisphere: An electrical stimulation mapping investigation in 117 patients. **J Neurosurg** 71:316–326, 1989.
57. Oppenheimer SM, Gelb A, Girvin JP, Hachinski VC: Cardiovascular effects of human insular cortex stimulation. **Neurology** 42:1727–1732, 1992.
58. Paulesu E, Frith CD, Frackowiak RSJ: The neural correlates of the verbal component of working memory. **Nature** 362:342–344, 1993.
59. Penfield W, Faulk ME Jr: The insula: Further observations on its function. **Brain** 78:445–470, 1955.
60. Petit L, Orssaud C, Tzourio N, Salamon G, Mazoyer B, Berthoz A: PET study of voluntary saccadic eye movements in humans: Basal ganglia-thalamocortical system and cingulate cortex involvement. **J Neurophysiol** 69:1009–1017, 1993.

61. Platel H, Price C, Baron JC, Wise R, Lambert J, Frackowiak RSJ, Lechevalier B, Eustache F: The structural components of music perception: A functional anatomical study. **Brain** 120:229–243, 1997.
62. Price CJ, Moore CJ, Humphreys GW, Frackowiak RSJ, Friston NJ: The neural regions sustaining object recognition and naming. **Proc R Soc Lond B Biol Sci** 263:1501–1507, 1996.
63. Rauch SL, Savage CR, Alpert NM, Miguel EC, Baer L, Breiter HC, Fischman AJ, Manzo PA, Moretti C, Jenike MA: A positron emission tomographic study of simple phobic symptom provocation. **Arch Gen Psychiatry** 52:20–28, 1995.
64. Rivier F, Clarke S: Cytochrome oxydase, acetylcholinesterase, and NADPH diaphorase staining in human supratemporal and insular cortex: Evidence of multiple auditory areas. **Neuroimage** 6:288–304, 1997.
65. Roper SN, Lévesque MF, Sutherling WW, Engel J Jr: Surgical treatment of partial epilepsy arising from the insular cortex. **J Neurosurg** 79:266–269, 1993.
66. Rosner SS, Rhoton AL Jr, Ono M, Barry M: Microsurgical anatomy of the anterior perforating arteries. **J Neurosurg** 61:468–485, 1984.
67. Rumsey JM, Horwitz B, Donohue BC, Nace K, Maisog JM, Andreason P: Phonological and orthographic components of word recognition: A PET-rCBF study. **Brain** 120:739–759, 1997.
68. Sallinen PK, Haapasalo HK, Visakorpi T, Helén PT, Rantala IS, Isola JJ, Helin HJ: Prognostication of astrocytoma patient survival by Ki67 (MIB-1), PCNA, and S-phase fraction using archival paraffin-embedded samples. **J Pathol** 174:275–282, 1994.
69. Schmahmann JD, Leifer D: Parietal pseudothalamic pain syndrome: Clinical features and anatomic correlates. **Arch Neurol** 49:1032–1037, 1992.
70. Schneider RJ, Nelson RJ, Friedman DP, O'Neill JB, Mishkin M: The granular insula in the rhesus monkey: Somatic sensory properties. **Soc Neurosci Abstr** 10:496, 1984.
71. Seitz RJ, Huang Y, Knorr U, Tellmann L, Herzog H, Freund HJ: Large-scale plasticity of the human motor cortex. **Neuroreport** 6:742–744, 1995.
72. Shuren J: Insula and aphasia. **J Neurol** 240:216–218, 1993.
73. Silfvenius H, Gloor P, Rasmussen T: Evaluation of insular ablation in surgical treatment of temporal lobe epilepsy. **Epilepsia** 5:307–320, 1964.
74. Skirboll SS, Ojemann GA, Berger MS, Lettich E, Winn R: Functional cortex and subcortical white matter located within gliomas. **Neurosurgery** 38:678–685, 1996.
75. Smith-Swintosky VL, Plata-Salaman CR, Scott TR: Gustatory neural coding in the monkey cortex: Stimulus quality. **J Neurophysiol** 66:1156–1165, 1991.
76. Suzuki J, Sato S: The new transinsular approach to the hypertensive intracerebral hematoma. **Jpn J Surg** 2:47–52, 1972.
77. Tanigushi T, Aoki N, Sakai T, Mizutani H: "Transinsular approach" for the treatment of a medial temporal arteriovenous malformation. **Neurosurgery** 32:863–866, 1993.
78. Türe U, Yasargil DCH, Al-Mefty O, Yasargil MG: Topographic anatomy of the insular region. **J Neurosurg** 90:720–733, 1999.
79. Vanaclocha V, Saiz-Sapena N, Garcia-Casasola C: Surgical treatment of insular gliomas. **Acta Neurochir (Wien)** 139:1126–1135, 1997.
80. Varnavas GG, Grand W: The insular cortex: Morphological and vascular anatomic characteristics. **Neurosurgery** 44:127–138, 1999.
81. Vincentelli F, Caruso G, Andriamamonjy C, Rabehanta P, Graziani N, Grisoli F, Gouaze A, Vigouroux RP: Micro-anatomy of collateral perforating branches of the middle cerebral artery [in French]. **Neurochirurgie** 36:3–15, 1990.
82. Weiller C, Chollet F, Friston KJ, Wise RJ, Frackowiak RSJ: Functional reorganization of the brain in recovery from striatocapsular infarction in man. **Ann Neurol** 31:463–472, 1992.
83. Weingart J, Olivi A, Brem H: Supratentorial low-grade astrocytomas in adults. **Neurosurg Q** 1:141–160, 1991.
84. Williamson JW, Nobrega AC, McColl R, Mathews D, Winchester P, Friberg L, Mitchell JH: Activation of the insular cortex during dynamic exercise in humans. **J Neurophysiol** 503:277–283, 1997.
85. Xu X, Fukuyama H, Yazawa S, Mima T, Hanakawa T, Magata Y, Kanda M, Fujiwara N, Shindo K, Nagamine T, Shibasaki H: Functional localization of pain perception in the human brain studied by PET. **Neuroreport** 8:555–559, 1997.
86. Yakovlev PI: Pathoarchitectonic studies of cerebral malformations. **J Neuropathol Exp Neurol** 18:22–55, 1959.
87. Yasargil MG, von Ammon K, Cavazos E, Doczi T, Reeves JD, Roth P: Tumours of the limbic and paralimbic systems. **Acta Neurochir (Wien)** 118:40–52, 1992.
88. Zelkowicz BJ, Herbster AN, Nebes RD, Mintun MA, Becker JT: An examination of regional cerebral blood flow during object naming tasks. **J Int Neuropsychol Soc** 4:160–166, 1998.
89. Zentner J, Meyer B, Stangi A, Schramm J: Intrinsic tumors of the insula: A prospective surgical study of 30 patients. **J Neurosurg** 85:263–271, 1996.

COMMENTS

The authors present a model study, showing the importance of functional neurosurgery and a knowledge of physiopathological and clinical neurophysiological findings in approaching eloquent areas of the brain. Because of the many complications resulting from resection of the insular area, either in epilepsy or tumor surgery, this structure was practically interdicted to younger neurosurgeons 1 or 2 decades ago. The introduction of intraoperative direct cortical stimulation, subcortical stimulation, and electrocorticography to tumor surgery, associated with neuronavigation, perioperative ultrasound, preoperative three-dimensional angiocomputed tomographic scanning, and the use of the stereotactic image-guided systems, has made it possible to remove these difficult lesions more extensively.

The authors display profound and up-to-date knowledge of the physiopathological, cytoarchitectonic, and functional interface of the insular cortex region. This region has long been considered enigmatic by nonexperimental scientists who have analyzed the consequences, feasibility, and limitations of insular surgery in an attempt to identify and preserve eloquent sites through language mapping and evaluating the distance of the internal capsule from tumor neuronal boundaries throughout the surgical procedure. Many complex and important functions of the insula have been demonstrated and emphasized by other authors mentioned in the article's references: sensory and visceral functions, such as taste, olfaction, esophageal sensation, and partial visceral seizures; tactile discrimination; recognition and recall; pain perception; motor function as a secondary motor area; limbic integration and behavior; and vestibular, auditory, cognitive, and language roles. These are very important functions of the insula that should be preserved by the skilled neurosurgeon.

We were glad to verify that these present acquisitions of applied neurophysiology coincide with some of our earlier

experimental studies of insular function at Dr. Paul MacLean's laboratory at the National Institutes of Health. We used awake squirrel monkeys and performed neuronal unit studies with stereotactic implanted insular glass and platinum microelectrodes. We have studied exteroceptive gustatory, somatic, auditory, and visual inputs in 1800 cell units of Brockaus' claustrocortex, claustrum, and frontal and temporal operculi and found important responses in all of these inputs. One interesting type of cell, responding to threatening and menacing objects, also was found in the claustrocortex and frontal operculum but has not yet been described (1). The authors have shown the importance of brain mapping methods, using functional and anatomic boundaries to perform glioma surgery in deep insular locations, thus minimizing the risk of postoperative sequelae and optimizing the quality of the resection.

Raul Marino, Jr.
São Paulo, Brazil

1. Sudakov K, MacLean PD, Reeves A, Marino R: Unit study of exteroceptive inputs to claustrocortex in awake, sitting, squirrel monkey. **Brain Res** 28:19–34, 1971.

In this study of 12 insular low-grade glioma resections, the authors have tried to improve the physiological understanding of the function of the insula and the feasibility of surgical therapy using neuronavigation and electrophysiological methods. The authors describe in a consistent way the advantages of insular glioma surgery. In addition, they extensively discuss physiological aspects of the insular lobe and include major contributions from the literature concerning insular function. The inclusion of techniques such as neuronavigation, ultrasonography, and motor mapping makes the article informative. The use of these techniques is particularly helpful in the resection of large insular tumors. The standard of controlling resection with early postoperative magnetic resonance imaging is also to be commended. In my experience, I only can confirm the value of motor mapping in insular tumors.

This study would have profited from an increase in the number of patients. The small body of literature on surgery for insular glioma is nicely supplemented by this article, with a valuable context on the physiological aspects and on functionally guided neurosurgery.

Johannes Schramm
Bonn, Germany

In this concise and well-written report, Duffau et al. present their experience in managing 12 low-grade gliomas involving the insula. The authors sought to critically review the influence of intraoperative direct cerebral stimulation and neuronavigation on the operability of insular tumors and correlated their findings with the patients' functional outcome.

The true merit of this study lies in the use of cortical stimulation to delineate functional areas (e.g., internal capsule) as an adjunct in the surgical resection of these often formidable tumors. Neuronavigation, however, seems to have limited benefit as a result of the inherent structural movement factor.

The insula is formed of an invaginated set of five gyri constituting the floor of the sylvian fissure, and it receives its blood supply from the M2 and M3 branches (up to 80 tiny arteries) of the middle cerebral artery. In the experience of the senior commentator (MGY), tumors of the insula may involve the insula entirely with possible extension into the frontobasal and temporal mediobasal areas but, surprisingly, not into the basal ganglia.

We differ with the authors on the surgical strategy for the resection of insular tumors. With the use of microtechniques, the sylvian fissure ought to be opened along its entire length, while preserving sylvian and insular veins and thus achieving wide exposure of the insula, which would allow multiangle dissection of the tumor. This strategy also allows early devascularization of the tumor by coagulating the small arterial branches of M2 and M3. Also, these tumors often extend superiorly and inferiorly (2–4 cm) as far as the borderline of the circular insular sulcus and, therefore, are covered by the frontal, parietal, and temporal opercula. In the latter scenario, rather than direct retraction of these opercular zones, central enucleation of the tumor ought to be considered; this would provide the space needed to enter these subopercular areas (2). Intraoperative ultrasound can be helpful in identifying the residual portion of tumor.

The surgeon's appreciation of the anatomy of the lateral lenticulostriate group of arteries is among the most crucial factors in insular tumor resection. These lenticulostriate vessels originate on the inferomedial surface of M1, most commonly arising as one single-stem artery that subsequently divides into multiple small branches. Less commonly, they arise as two main-stem arteries or as multiple small vessels directly off the M1 or the proximal M2. An important variation of the origin of the lenticulostriates occurs in less than 3% of cases, namely the striate vessels arise from the lateral fronto-orbital artery (1). Intraoperative micro-Doppler can be an adjunct in identifying the vicinity of the hemodynamic flow within these critical lenticulostriate vessels proximal to and within the lentiform nucleus.

The authors have presented a thoughtful and critical review of their own data, as well as that of the literature, aiming to assess anatomic and physiological variables in the surgical management of insular tumors.

M. Gazi Yaşargil
Little Rock, Arkansas
Saleem I. Abdulrauf
St. Louis, Missouri

1. Yasargil MG: *Microneurosurgery: Microsurgical Anatomy of the Basal Cisterns and Vessels of the Brain.* Stuttgart, Georg Thieme, 1984, vol I, pp 77–83.
2. Yasargil MG: *Microneurosurgery: Microneurosurgery of CNS Tumors.* Stuttgart, Georg Thieme, 1996, vol IVB, pp 263–268.